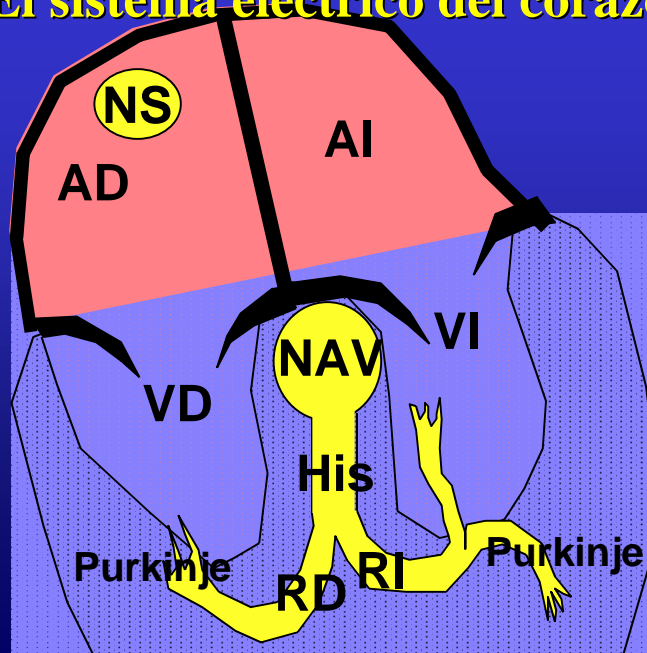


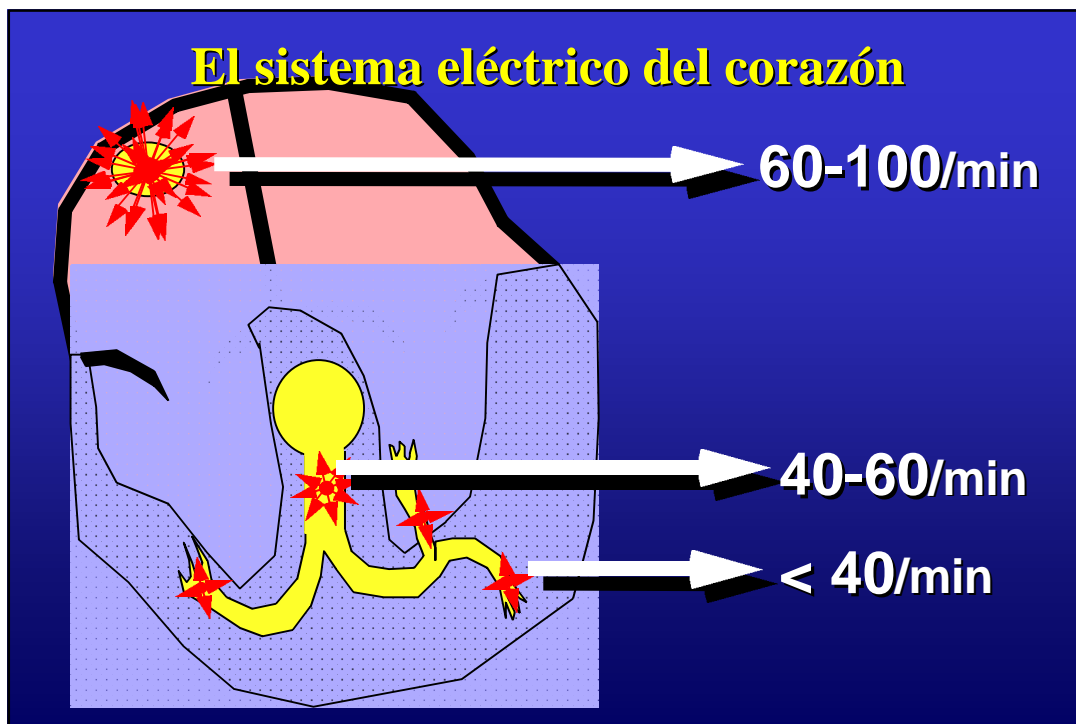
Curso ECG

Dr. Raúl Moreno

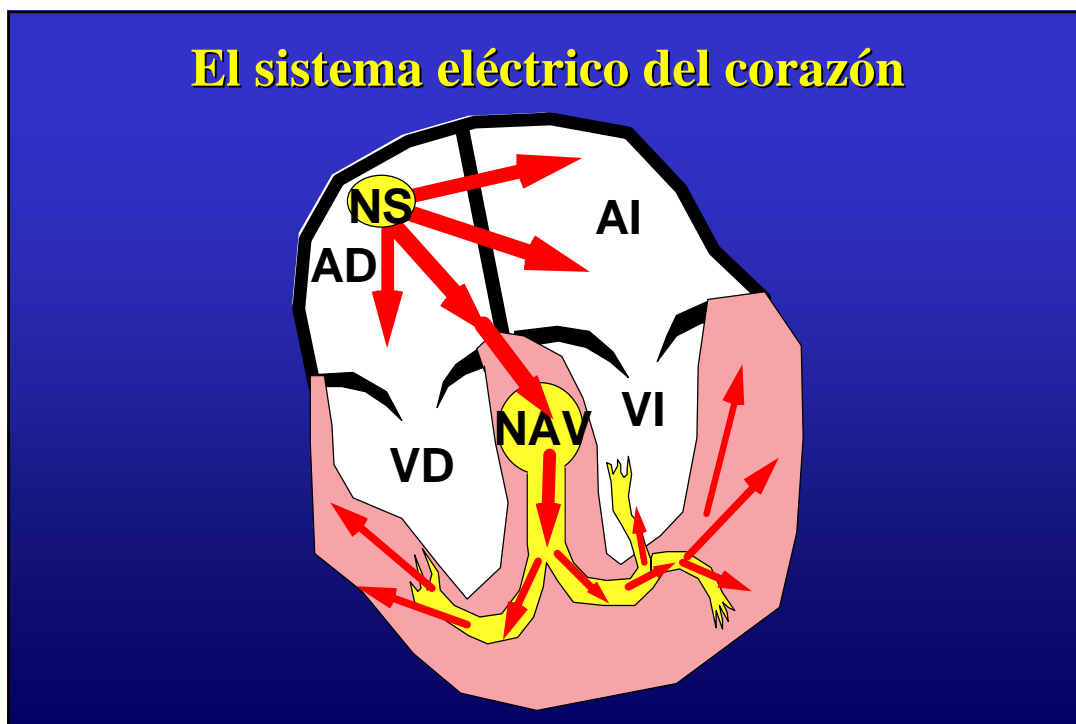
El sistema eléctrico del corazón



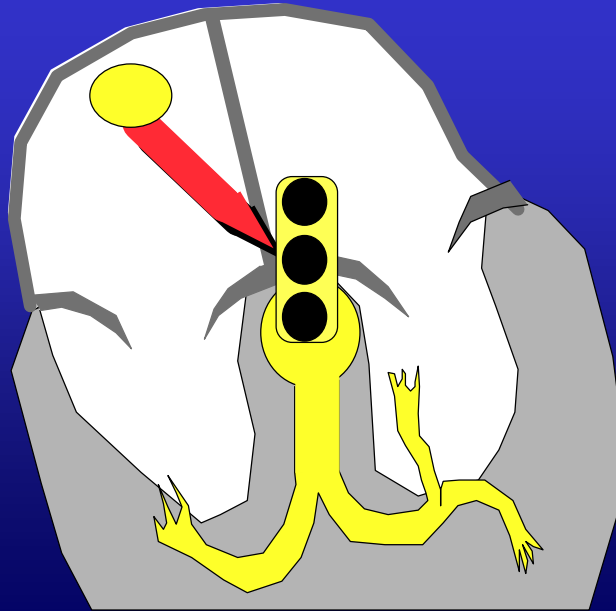
El sistema eléctrico del corazón



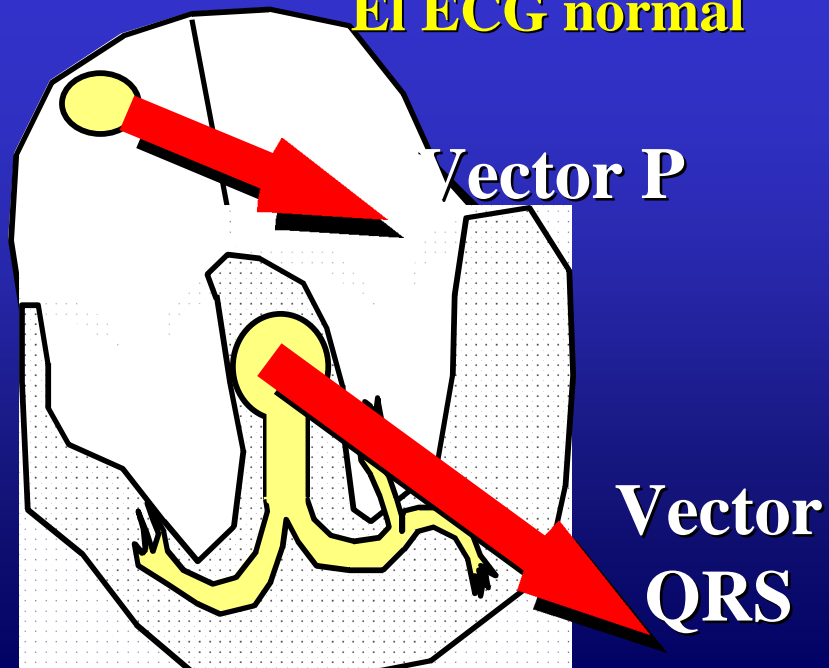
El sistema eléctrico del corazón

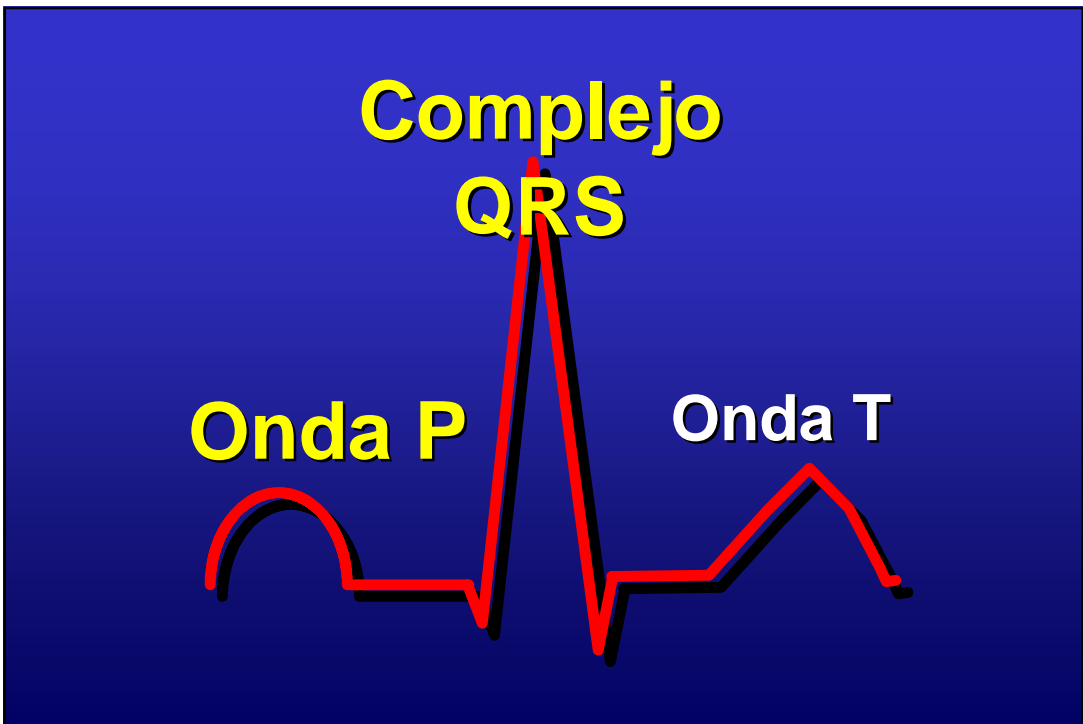
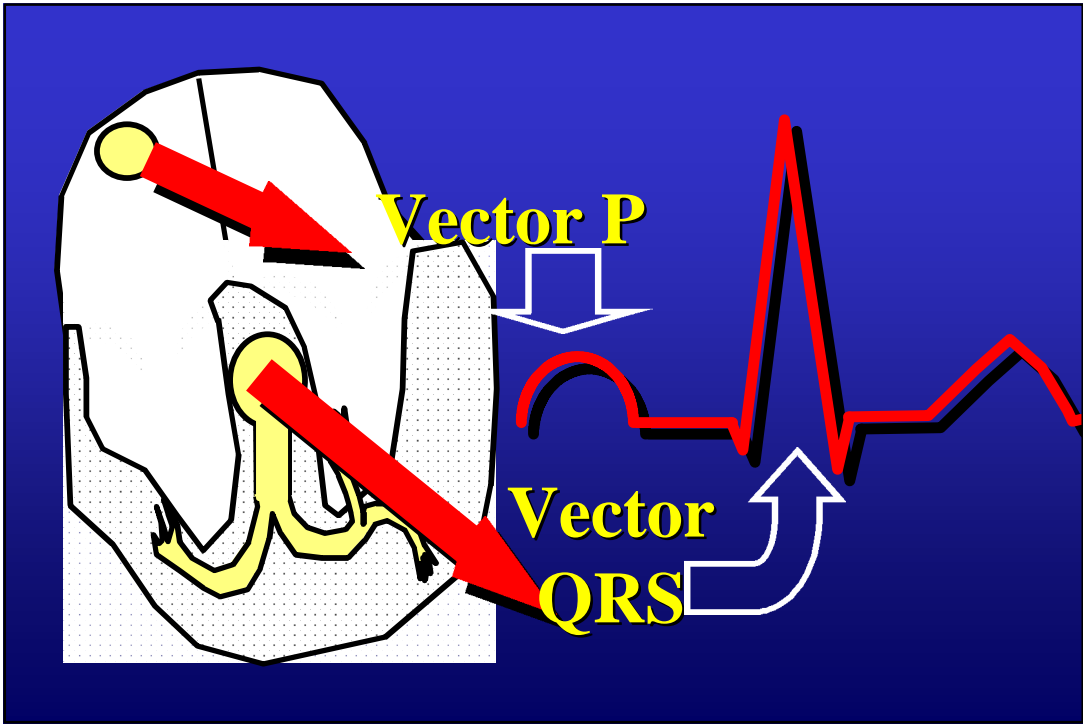


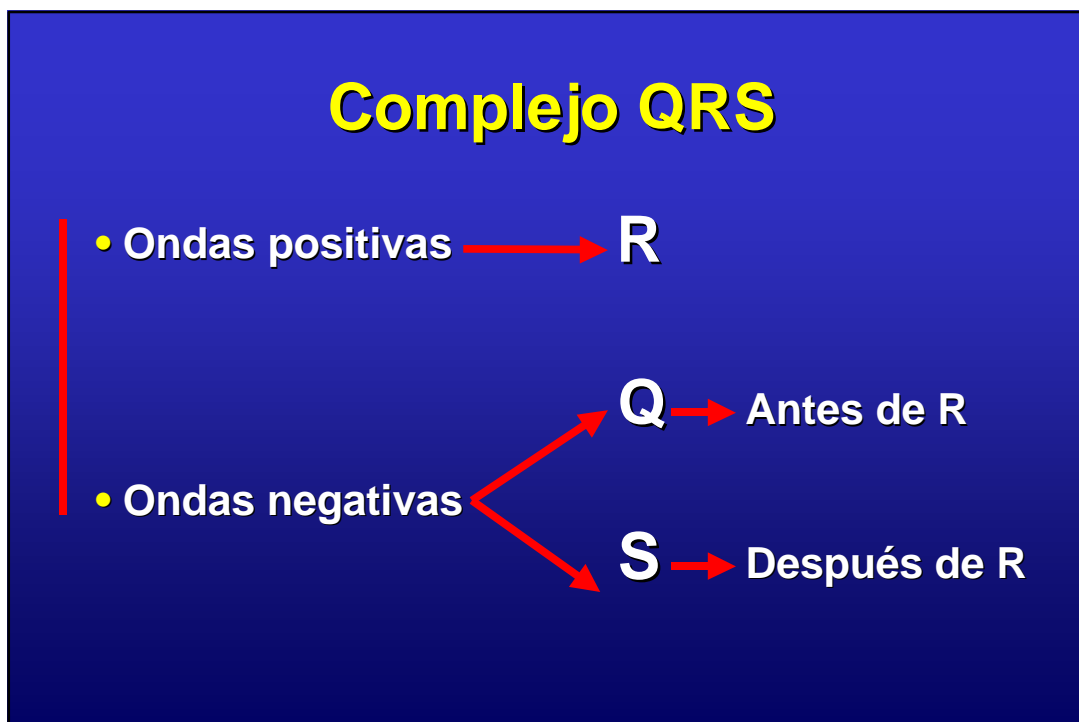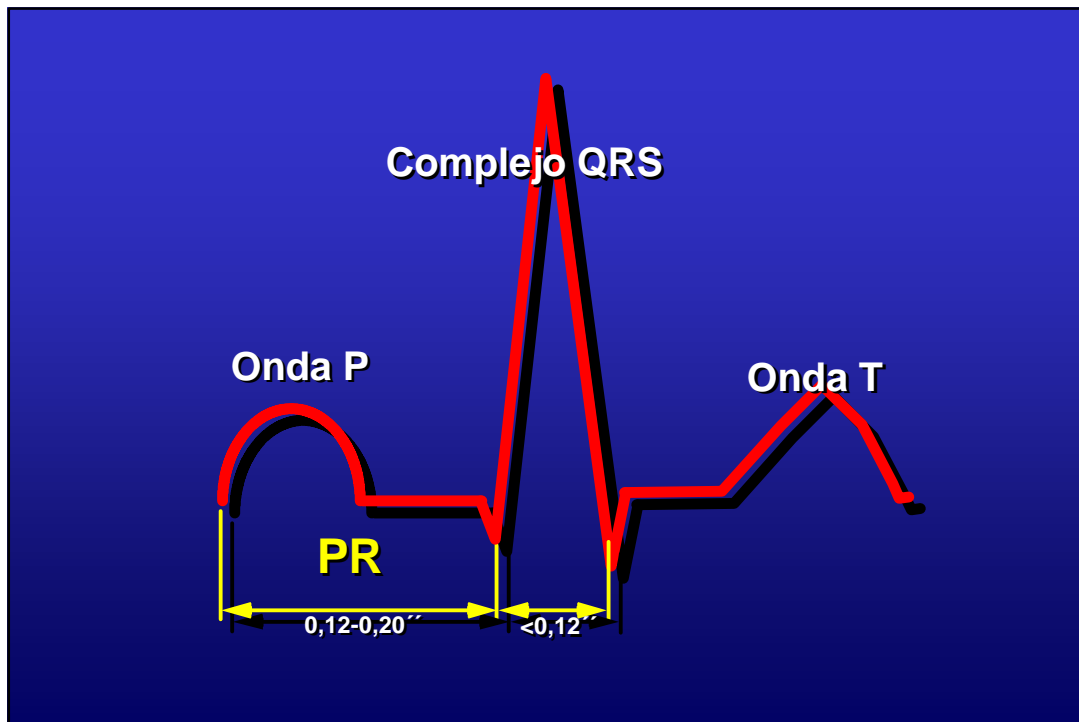
Función del nódulo AV

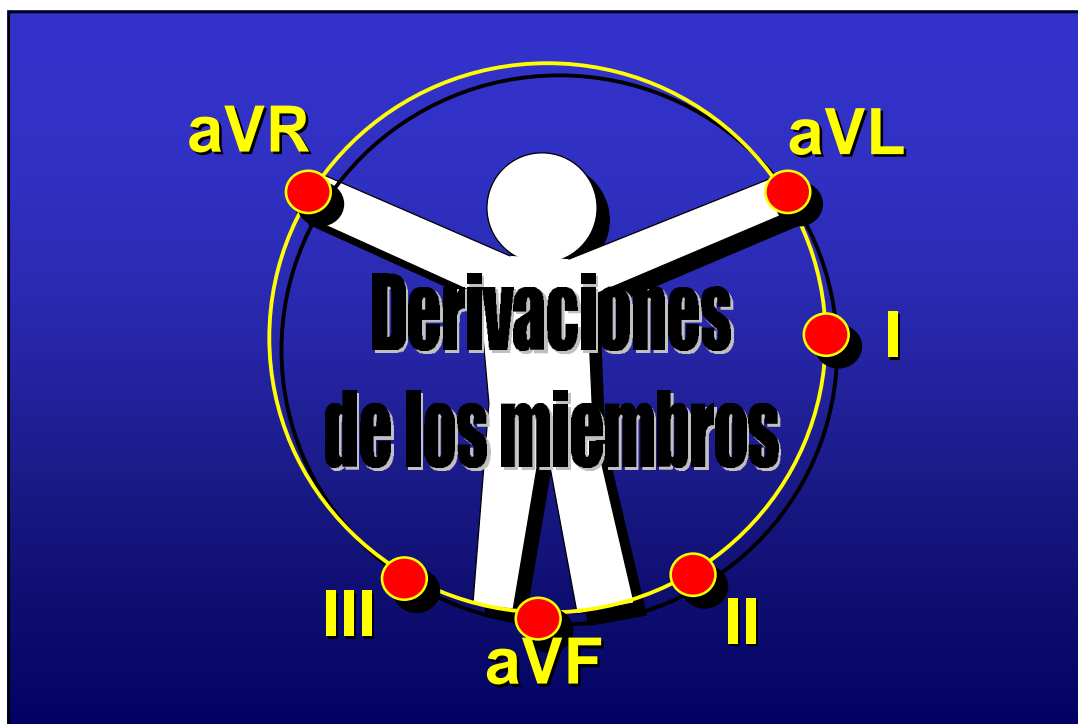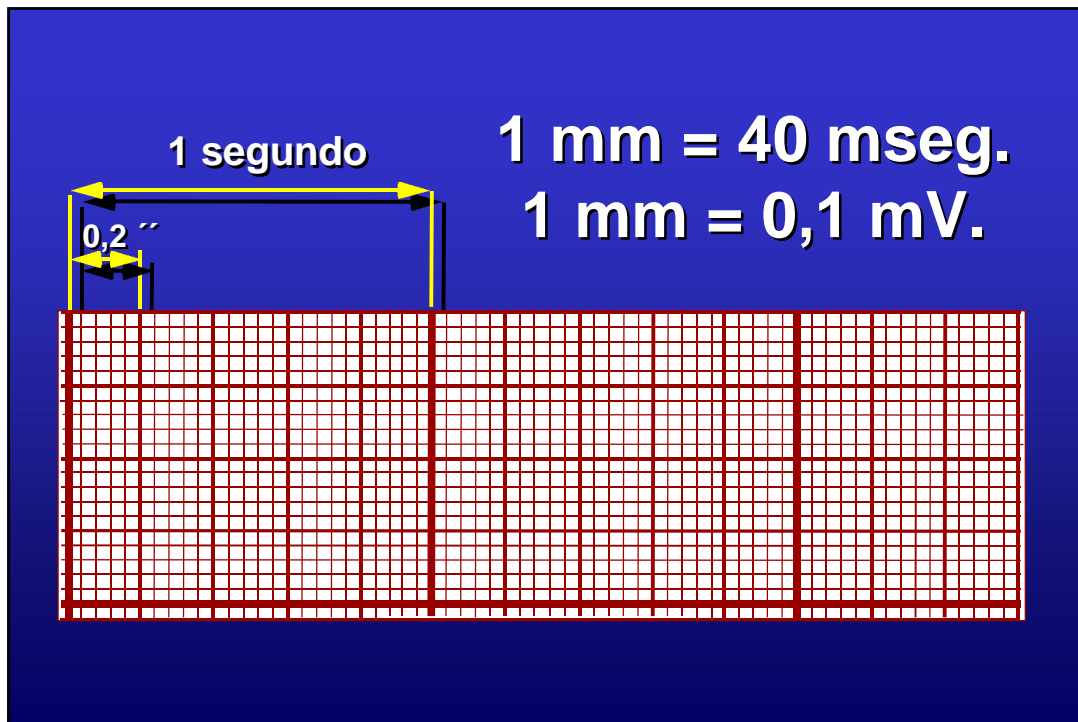


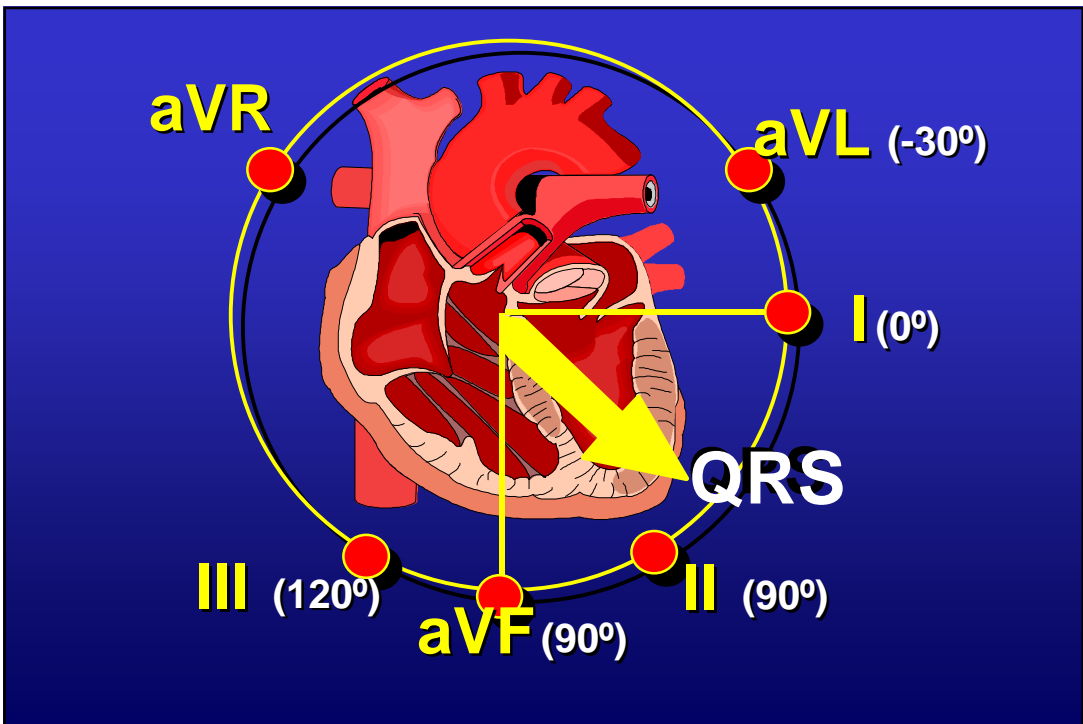
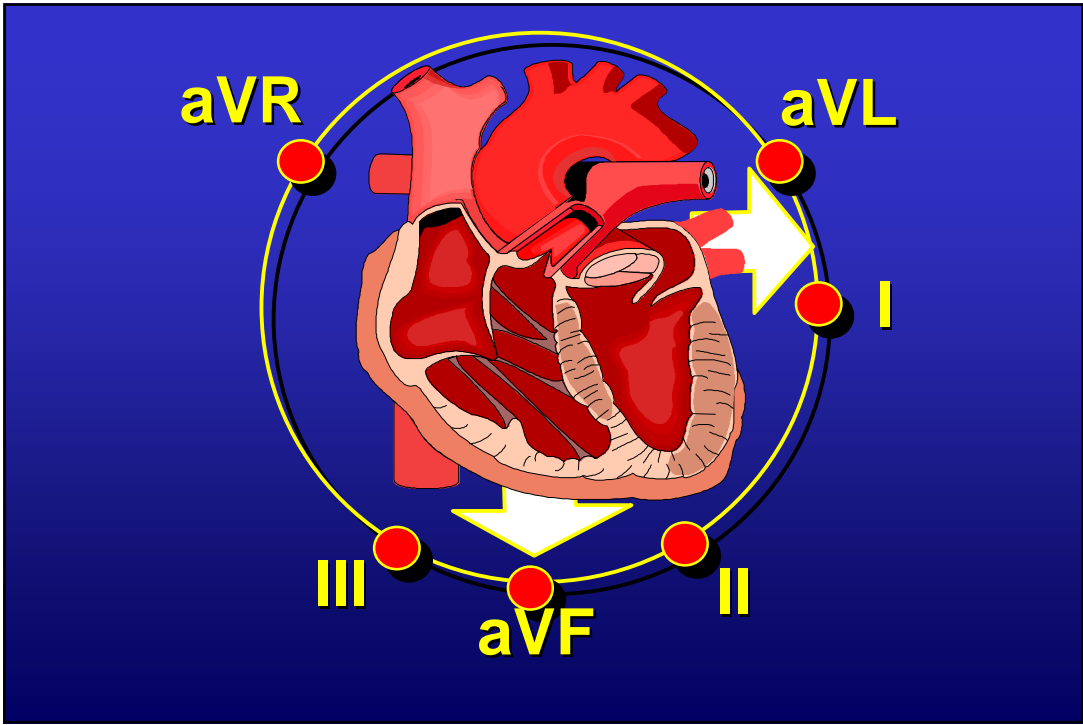
El ECG normal



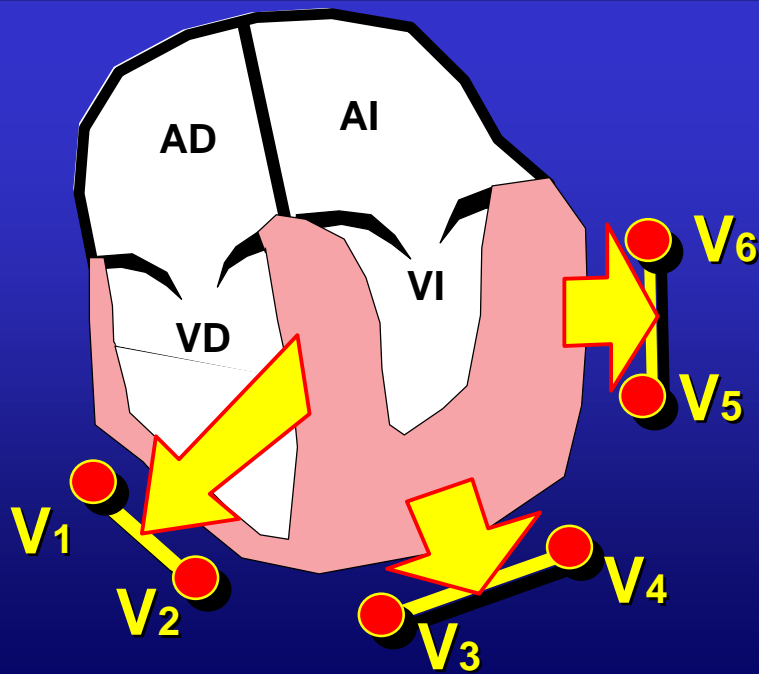
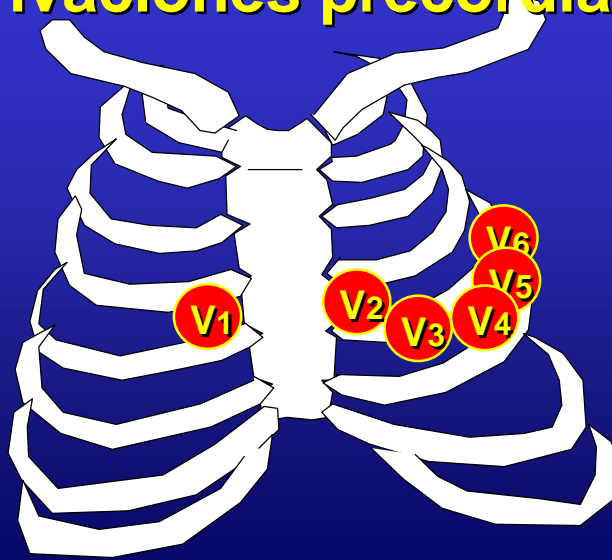



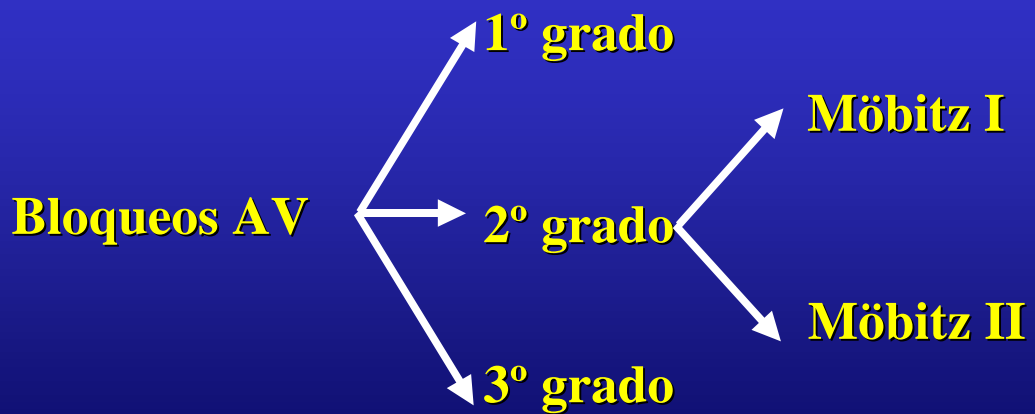
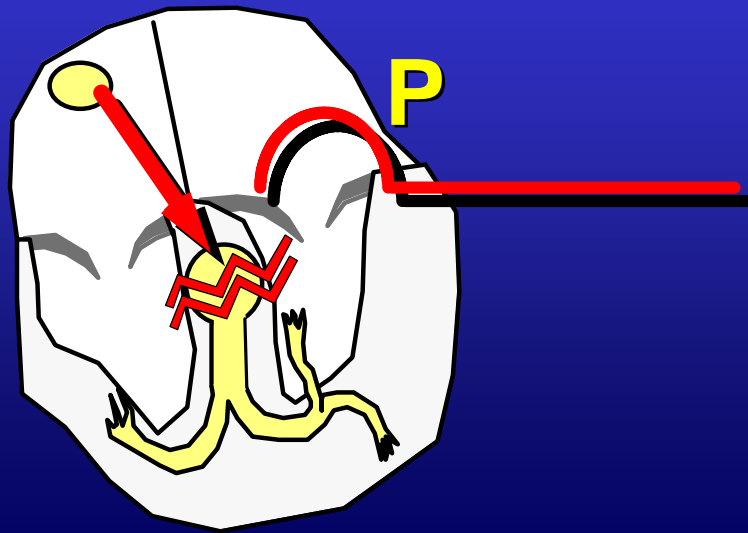




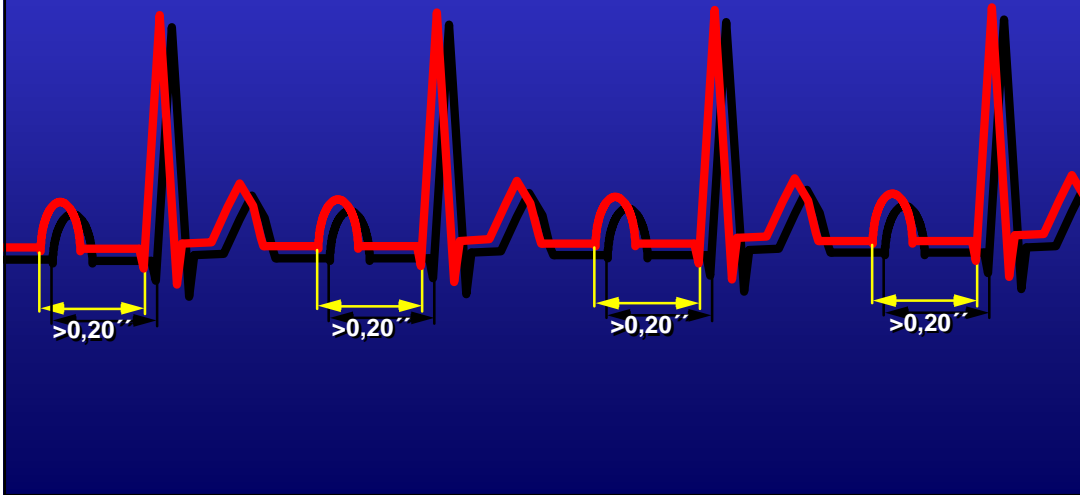
Derivaciones precordiales



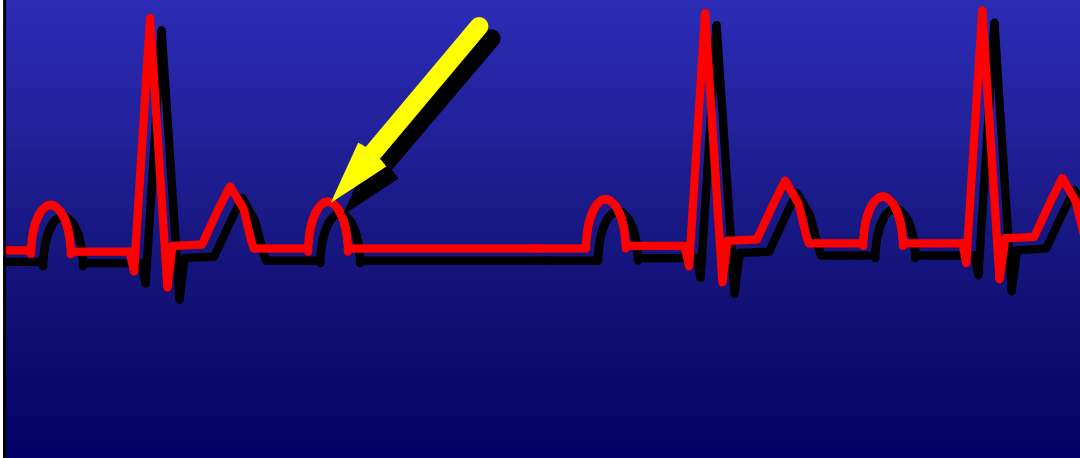
Trastornos de la conducción AV



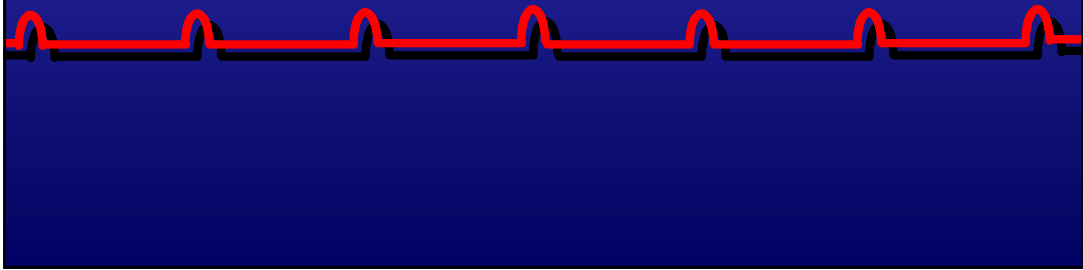
- **Bloqueo AV de primer grado.**



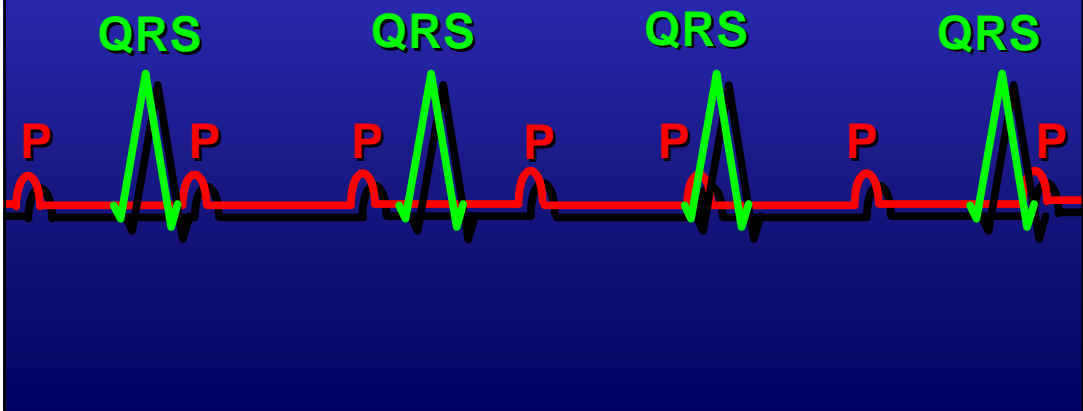
- **Bloqueo AV de 2º grado.**




- **Bloqueo AV de tercer grado.**



- **Bloqueo AV de tercer grado.**



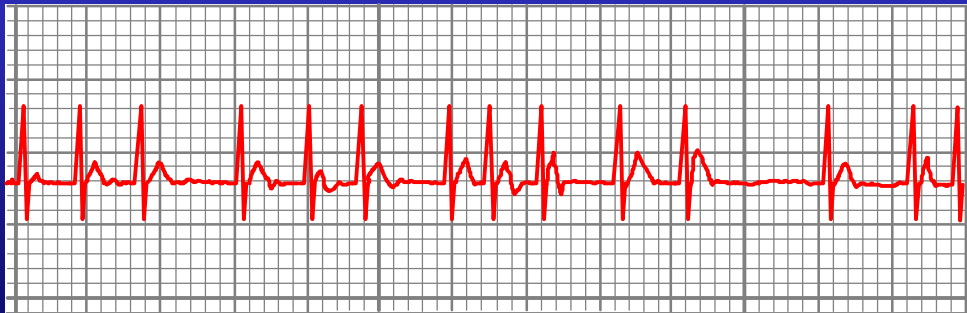
Infarto Agudo de Miocardio



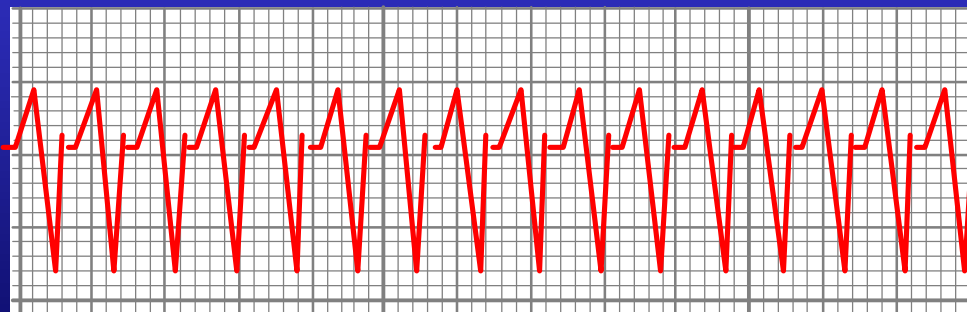
Infarto: Localización

- **II, III, aVF** → **Inferior**
- **V1-V2** → **Septal**
- **V3-V4** → **Anterior**
- **V5-V6-I, aVL** → **Lateral**

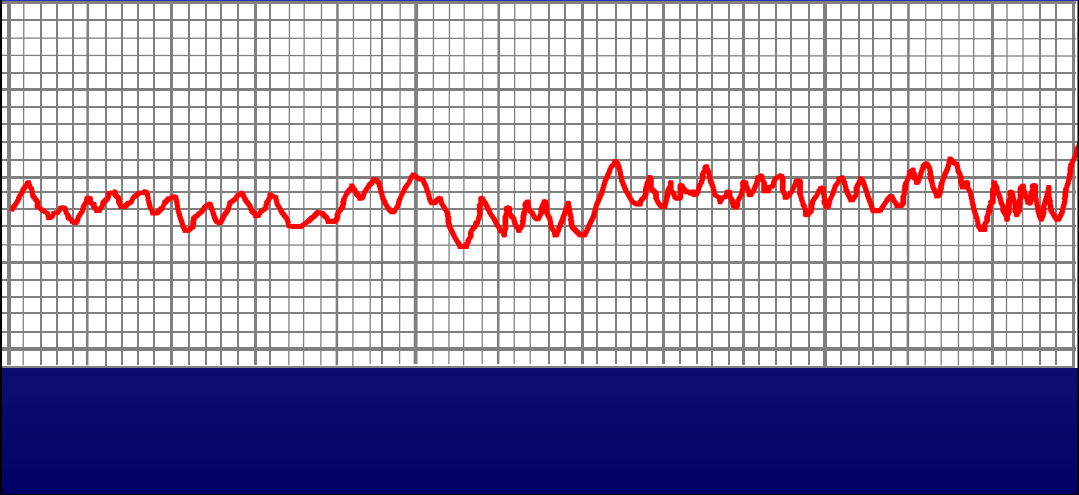
Fibrilación Auricular



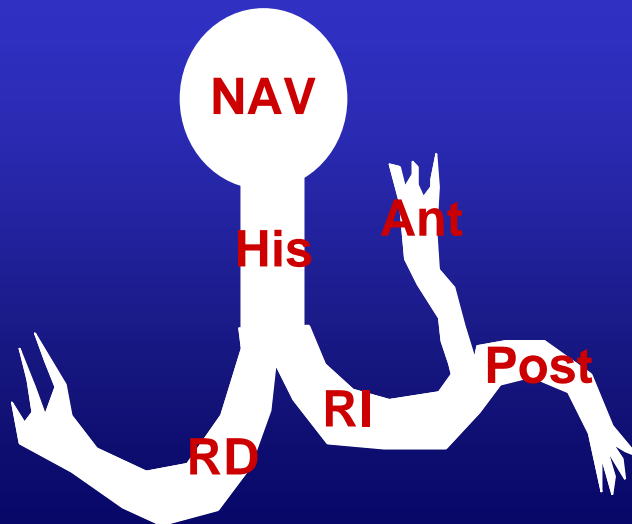
Taquicardia ventricular



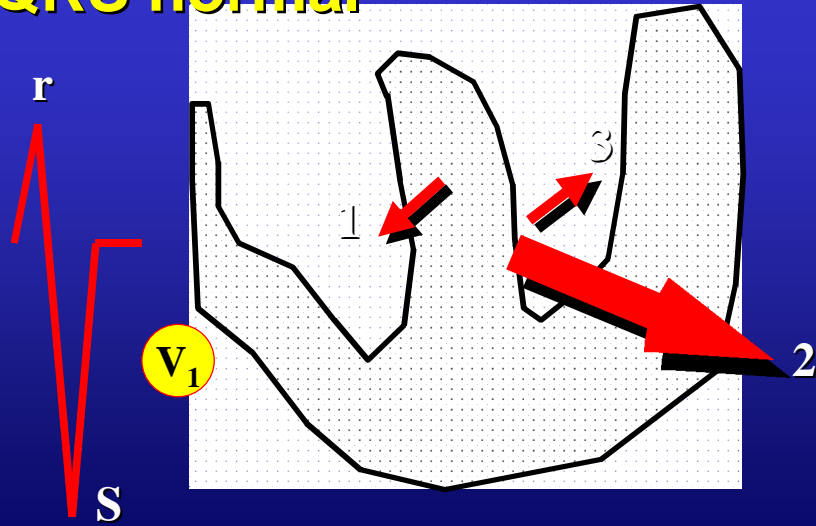
Fibrilación ventricular



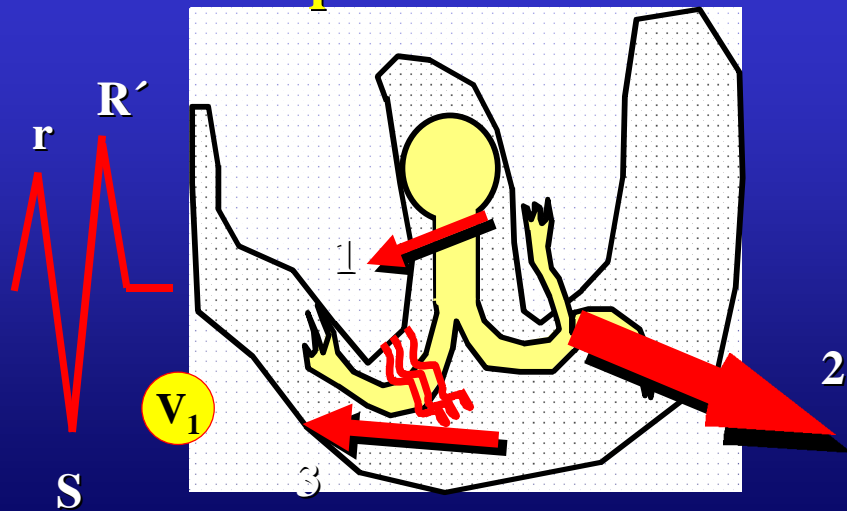
Bloqueos de rama



QRS normal



Bloqueo de RD



Bloqueo de RI

